

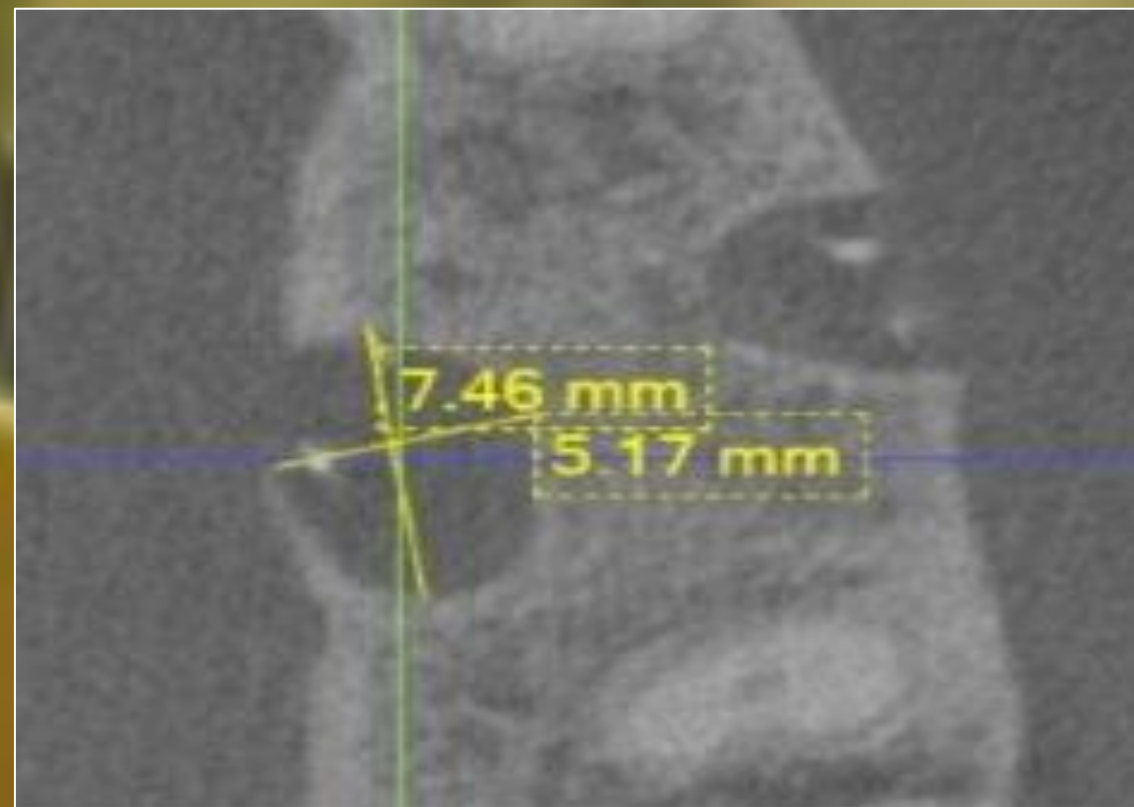
# SIZE MATTERS

## Radiographic Considerations in Endodontic Microsurgery

Brandon S. Astin, DMD; André K. Mickel, DDS, MSD

Case Western Reserve University School of Dental Medicine, Graduate Endodontics, Cleveland, OH

### SIZE of Lesion



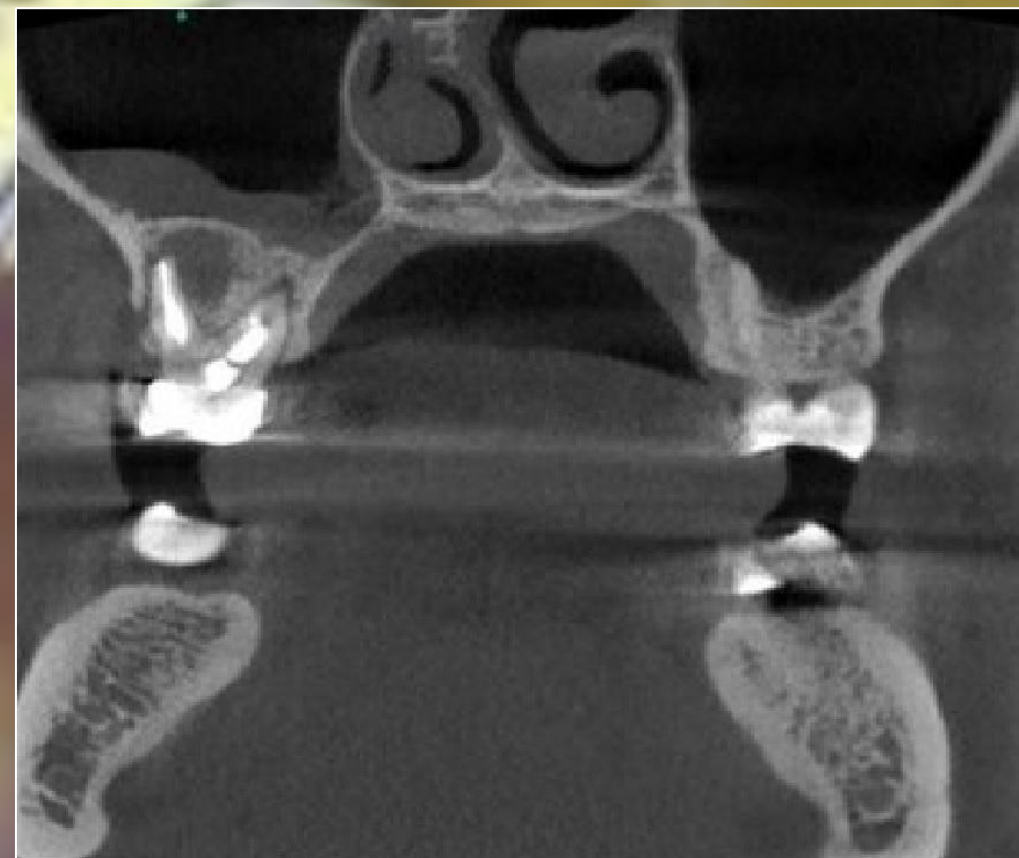#### Larger lesions

- Larger hole in bone
- Larger flap
- Additional bleeding

### SIZE of 'safe zone'

#### Proximity to vital structures

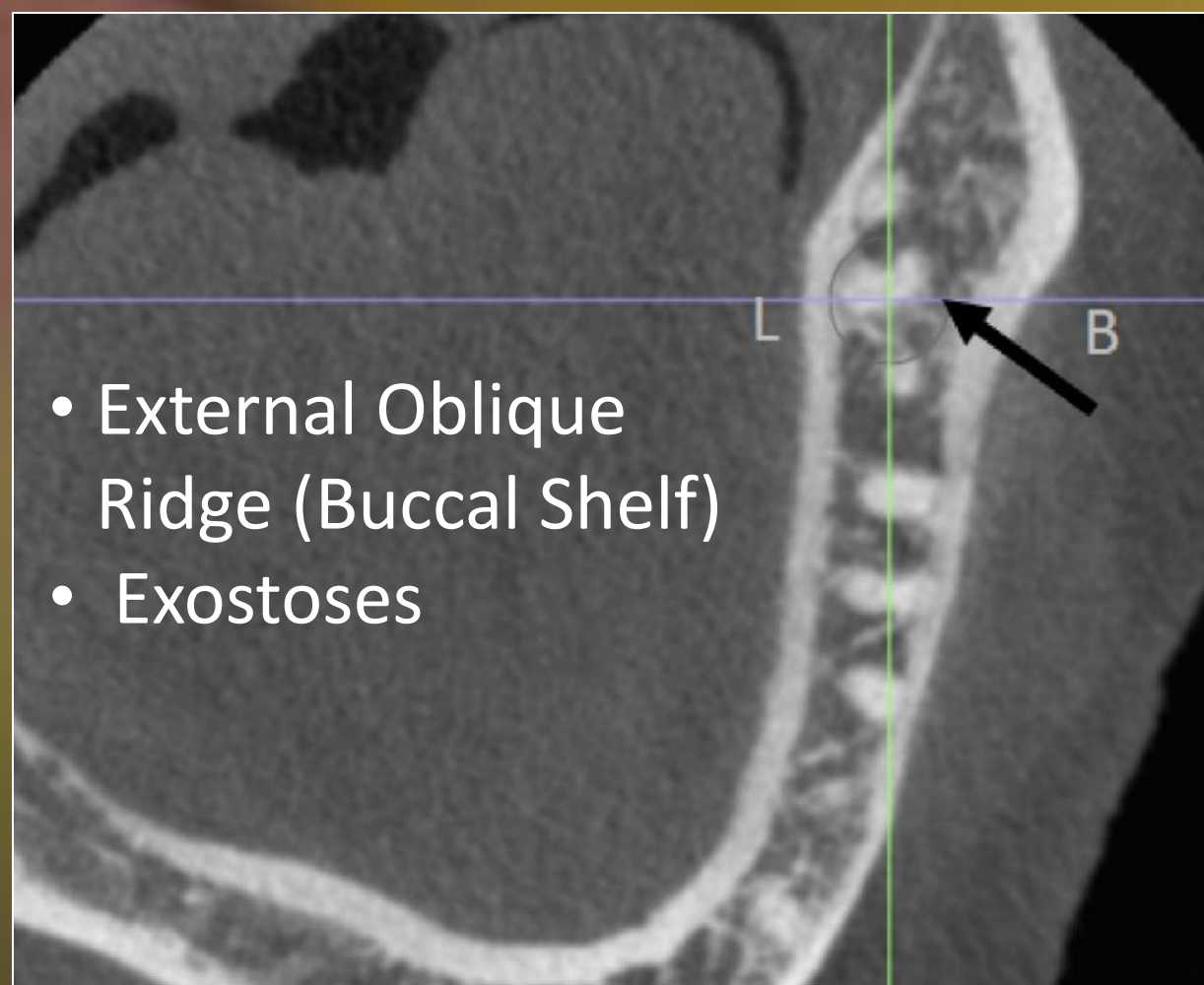
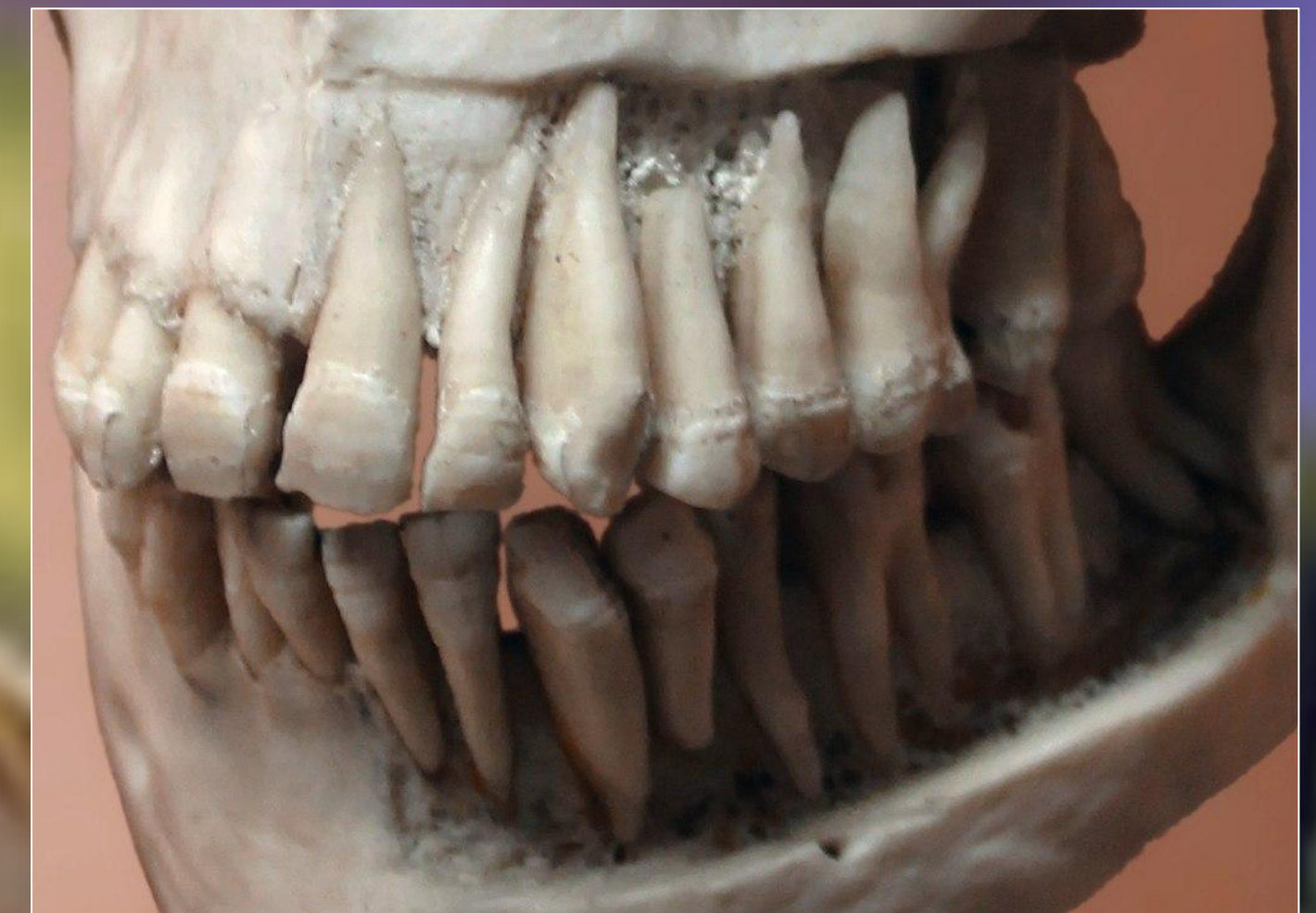- Maxillary Sinus
- Inferior Alveolar Nerve/Mental Foramen
- Adjacent teeth



### SIZE of Root

#### Considerations for Long Root **SIZE**

- Depth of surgical access into the vestibule
- Encroachment on vital structures



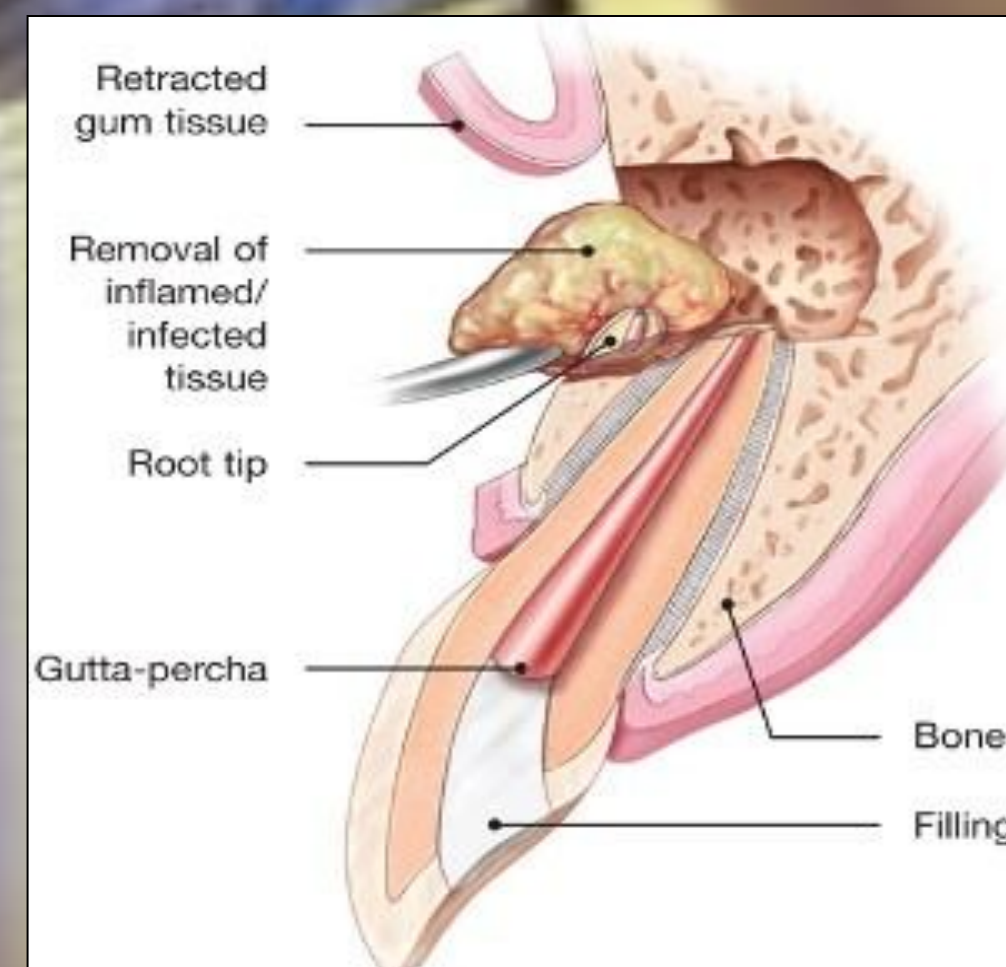
- External Oblique Ridge (Buccal Shelf)
- Exostoses

### SIZE of surgical obstacles

#### Discussions with

#### Patient

- Informed (SIZES) Consent
- Biopsy



#### Considerations for Short Root **SIZE**

- Crown:Root Ratio (Conservative resections required)
- Incisional access vs Smile-line Esthetics

