 0039–6109/97 $0.00 + .20

THE ACUTE ABDOMEN

An Overview and Algorithms

Ronald F Martin, MD, and Ricardo L Rossi, MD

The acute abdomen remains a challenge to surgeons and other physicians. Abdominal pain is the most common cause for hospital admission in the United States.[7] Since the term *acute abdomen* inherently implies a suddenness of onset, the clinical course of abdominal symptoms can range from minutes to hours to weeks. Furthermore, the acute abdomen can present as acute exacerbation of chronic problems, such as chronic pancreatitis, vascular insufficiency, metabolic abnormalities, or collagen vascular diseases. The term, acute abdomen, is often used synonymously for a condition that requires immediate operative intervention. Those patients, who require immediate operation, represent only a subset of patients with an acute abdomen. This article is devoted entirely to the discussion of the patient with an acute abdomen. It has been written with the intent of not rehashing what has already been discussed in literature regarding this topic, but to specifically address the question "Has anything changed?" The topics in this article range from bowel obstruction, with perforation and diffuse peritonitis, to ruptured abdominal aneurysms, to narcotic withdrawal, to hereditary Mediterranean fever. The techniques for management of the acute abdomen range from pharmacologic, to laparoscopic, to formal laparotomy. The authors would submit that although many of the basic principles in managing the patient with the acute abdomen have remained intact, a

From the Division of General Surgery, Maine Medical Center and Mercy Hospitals, Portland, Maine, and the Department of Surgery, University of Vermont, Burlington, Vermont (RFM); and the Department of General Surgery, Hospital Clinico, Facultad de Medicina; Pontificia Universidad Catolica de Chile; and the Clinica Alemana, Santiago, Chile (RLR)

great deal about our understanding and management of these patients has changed.

ASSESSMENT OF THE PATIENT WITH AN ACUTE ABDOMEN

It cannot be sufficiently emphasized that the most important components of the evaluation of the patient with an acute abdomen are a well-conducted history and a proper physical examination. Nearly every surgeon has been consulted to evaluate a patient with abdominal pain, and has been promptly regaled with a myriad of test results and radiographic findings (of which few were actually helpful), only to realize that the patient was able to relate the exact diagnosis by history. In the conscious and responsive patient, the diagnosis can frequently be made by taking a thorough history alone.

A proper history of the patient with acute abdominal pain must include not only the history of the present condition, but also the appropriate family history, social history, drugs taken (licit and illicit), and past medical history. By reviewing other aspects of the patient's history, one might uncover potentially unusual causes of abdominal pain such as heritable metabolic disorders, familial blood dyscrasias, toxic ingestions, acute withdrawal, acute exacerbations of chronic problems (chronic pancreatitis, inflammatory bowel disease), and nonabdominal causes of abdominal pain (myocardial ischemia, pleurisy, etc.).

The history of the present condition must also be taken thoroughly. Key elements of the present history are: age; time of onset of the pain and its acuteness; activity of the patient when the pain began; the location and character of the pain; radiation of the pain to other areas; presence of nausea, vomiting, or anorexia; temporal progression of the location or nature of the pain; changes in bowel habits; and menstrual history. Each of these features contributes significantly to the ability to formulate a differential diagnosis.

Age is useful in that certain conditions are clearly limited to specific age groups. The entire collection of maladies that can affect women of reproductive age are examples. Additionally intestinal intussusception is generally limited to children 2 years of age or less. Malignancies that obstruct or perforate are rarely seen in adults less than 30 or 40 years of age.

The onset of pain and its acuteness are also most useful. Pain that occurs suddenly or wakens a patient from sleep is frequently associated with gastrointestinal perforations or strangulations. As will be described later, the perception of pain is dependent upon stimulation of nociceptors. The pattern of slow insidious onset of pain suggests either inflammation of the visceral peritoneum without inflammation of the parietal peritoneum, or a contained process, such as an evolving abscess or retroperitoneal appendix. Crampy or colicky abdominal pain is associated with obstruction or partial blockage of a peristaltic organ. Examples

of this are biliary or renal colic and bowel obstruction. Progression of pain from a dull, achy, and poorly localized character to a sharper, constant, and better localized character is usually associated with progression of the disease process, and frequently portends the need for operative intervention.

Nausea and vomiting are frequently associated with a myriad of causes of the acute abdomen. The timing of the nausea or vomiting in relation to meals, as well as the factors that aggravate or alleviate, are essential in narrowing the diagnostic possibilities. Also, the characteristics of the emesis can be helpful in distinguishing the possible level of intestinal obstruction or the absence of biliary obstruction.

Changes in bowel habits such as diarrhea, constipation, or rectal bleeding can be associated with progressive obstructions from neoplasm or inflammatory bowel conditions. Rectal bleeding or Hemoccult-positive stool may also be a subtle indicator of possible bowel ischemia.

PAIN

Abdominal pain is most frequently the primary presenting complaint of the patient with an acute abdomen. A detailed understanding of the anatomic and physiologic properties that relate to abdominal pain is essential for the physician called upon to assist these patients.

The gastrointestinal tract and its associated organs are derived from the embryologic foregut, midgut, and hindgut. The foregut gives rise to the oropharynx, esophagus, stomach, and the first and second portions of the duodenum. It also gives rise to the pancreas, liver, biliary tree, and spleen. The midgut gives rise to the distal two portions of the duodenum, jejunum, ileum, appendix, ascending colon, and proximal two-thirds of the transverse colon. The distal transverse colon, descending and sigmoid colon, and rectum are derived from the hindgut. The hindgut ends at the interface of the ectodermal and endodermal layers at the dentate line.

The peritoneum is derived from the mesoderm. It consists of two double-layered sheets of cells that form the visceral and the parietal peritoneal layers. The visceral and parietal layers are in continuity, but have separately derived neural innervation. The visceral layer that covers the organs that protrude into the abdominal cavity is innervated by autonomic nerves (both sympathetic and parasympathetic). This visceral innervation is bilateral, and pain from these nerves is perceived as midline pain.[4] The parietal layer covers the inner surfaces of the abdominal parieties, and is innervated by somatic nerves of spinal origin. These nerves produce a sensation of pain in the area from which it originates.

The character of the pain is also dependent on the irritation of the visceral or the parietal layer. The visceral peritoneum contains C fibers. These are slow transmitters and produce dull, crampy pain of insidious nature. The somatic nerves are A-δ neurons. These are fast transmitters and give rise to sharp and exquisite pain. These fibers are located in the

skin, muscle, and parietal peritoneum. The fibers that innervate the abdomen arise from the T-7 to L-2 spinal nerves.[4] The umbilicus is at the level of T-10.

Since most intra-abdominal organs are insensitive to many forms of stimulation (burning, cutting, electrical, and the application of acid), they are sensitive to distention, stretch, traction, compression, and torsion. Ischemia and inflammation also stimulate the visceral neuronal response. It is not until the visceral process becomes transmural and inflames the parietal peritoneum that the pain localizes to the area of origin.

The genitourinary organs (kidneys, ureters, and bladder) share innervation with other visceral structures. Autonomic fibers from the celiac plexus, thoracic, and lumbar splanchnic nerves, the intermesenteric plexus, and the superior hypogastric plexus innervate the kidney and the upper ureters. The lower ureters and the urinary bladder and testes derive innervation from the pelvic autonomic ganglia.[5] The pancreas also has visceral afferent innervation from the celiac plexus and splanchnic nerves. These organs can initially present with the same kind of referred pain that is seen with inflammation of the intraperitoneal viscera. Additionally, inflammation of retroperitoneal structures, particularly the pancreas, can cause intraperitoneal irritation that further obscures the origin of pain.

PHYSICAL EXAMINATION

Physical examination of the patient with abdominal pain is of quintessential importance. Examination coupled with a proper history of the present condition will frequently secure the diagnosis.

The overall appearance of the patient can be quite helpful. Since a patient with ureteral lithiasis will writhe in agony, the patient with an intestinal perforation and diffuse peritonitis will usually lie very still. Patients who are relieved by leaning forward may have pancreatitis or perforation of the stomach into the lesser sac. The facial expression of the patient may signal whether the pain is crampy or constant in nature. Pallor may suggest anemia, or diaphoresis may accompany septicemia or vascular catastrophe. Changes in nailbeds may signify hypoxemia, evidence of emboli, or signs of hematologic crises.

Vital signs are just that. As in other diseases, tachycardia and hypotension signify hypovolemia and possible shock. Patients with acute gastric dilatation sometimes have bradycardia as a vagal response. Blood pressure should be measured in each arm, as a pressure gradient between arms may signify an acute aortic dissection. Attention should be given to the patient's ventilatory rate as well as pattern of ventilation. Patients with increased ventilatory rates who are not subjectively dyspneic may be trying to compensate for an underlying metabolic acidosis. Rapid ventilation may be accompanied by shallow effort and low tidal volumes to minimize the pain of fractured ribs or diaphragmatic excursion in the patient with peritonitis. Changes in thermoregulation are worrisome, although a normal temperature is not always a reliable predictor of the absence of disease.

Examination of the whole patient is mandatory to evaluate the patient with abdominal pain. The head and neck should be examined for intraoral lesions, scleral icterus, funduscopic signs of emboli, cervical adenopathy, cervical bruits, and jugular venous distention. The chest should be examined for patterns of movement as well as tenderness of the ribs and costochondral junctions. Pneumonia and pleuritic inflammation can present as upper abdominal pain. Therefore, auscultation of all lobes listening for rhonchi, rales, or pleuritic rubs is essential.

The skin of the abdomen and thorax should be examined for evidence of (herpes) zoster or other rash. Bruising over the flanks (Grey-Turner sign) suggests hemorrhagic pancreatitis. The flank should be palpated to elicit the tenderness of pyelonephritis or other musculoskeletal causes of abdominal pain.

Examination of the abdomen is an art. Although the novice examiner frequently leaps straight to mashing upon the area where the patient complains of pain, the seasoned examiner will avoid that area until absolutely necessary. The abdomen should be examined with the patient as comfortable as possible. Visual inspection is begun by looking for distention, hernias, abdominal pulsation, mass effect, and the pattern of movement with ventilation. The patient should be asked to point directly and precisely to the area that hurts most. Even if the patient cannot localize a specific point, useful information is provided. Failure to select a specific point suggests that the abdominal process has not markedly inflamed the parietal peritoneum. This may suggest that the process is either early in its course or is insulated from the parietal peritoneum. The patient who can precisely localize a point of maximal pain suggests the opposite and frequently narrows the diagnostic possibilities.

Auscultation of the abdomen gives information about bowel sounds and the presence or absence of abdominal bruits, and may help diagnose ascites. Since the literature and textbooks are replete with interpretations of characteristic bowel sounds, we find them less reliable. Abdominal bruits may be more useful in the diagnosis of certain vascular problems.

The surgeon is frequently the last in a long series of examiners. By the time he or she arrives, the patient with abdominal pain will often be apprehensive of abdominal palpation. It is sometimes preferable to ask the patient to cough to try to elicit a point of maximal tenderness. After this, the abdomen should be palpated with as little force as is required to evoke a response. All quadrants and the epigastrium should be examined carefully. Muscular tone, organomegaly, and presence of hernias, warmth, and pulsation should all be well noted. Shifting dullness on percussion of the abdomen may indicate the presence of ascites, while loss of hepatic dullness suggests free intraperitoneal air. Rebound tenderness refers to the patient experiencing pain upon rapid release of pressure from the examiner's hand. This maneuver is generally uncomfortable for the patient and rarely supplements the information obtained from gentle palpation.

Guarding refers to spasm of the muscle when it is palpated. *Voluntary* guarding is described when the patient can consciously eliminate the muscular response. *Involuntary* guarding is described when the response cannot be eliminated by the patient. The latter is more foreboding. Rigidity of the muscle is when the abdominal wall is tense and boardlike. It is usually associated with diffuse peritonitis. This finding can be difficult to ascertain in the morbidly obese patient. Sometimes muscular spasm is a result of a process limited to the abdominal wall, such as a rectus sheath hematoma. To try to differentiate between an intra-abdominal and intramural cause of tenderness and spasm, the patient should be palpated with the abdominal wall as relaxed as possible and with the abdominal wall forcefully contracted by raising the head to the chest. If the tenderness elicited on deep palpation is less with the abdominal muscles contracted, then the process is likely to be an intra-abdominal one. This is known as Fothergill's sign.

Various maneuvers are described to test for inflammation in the lower retroperitoneun and pelvis. The obturator sign is judged to be present if the patient experiences pain when the thigh is flexed and rotated through its range of motion. The pain will generally be felt in the hypogastrium. This test suggests that there is inflammation in the lower pelvis. Usual causes are ruptured appendix, tubo-ovarian abscess, or direct injury to muscles of the pelvic floor. The iliopsoas test is performed by having the patient lie on the contralateral side and fully extending the thigh. The test is positive if it evokes pain. Frequent causes of this are iliopsoas abscesses and appendiceal irritation (on the right side).

No abdominal exam is complete without a digital rectal exam. During my training it was often said that only two excuses were allowable for the patient to have the rectal exam deferred; the examiner has no fingers or the patient has no anus. We have never met a surgeon without fingers. Since that advice serves its purpose with some comic relief, it is not completely accurate. Rectal examination can allow detection of a pelvic collection or mass. It is particularly helpful in the patient with a rigid abdomen. The rectal vault should be inspected for the presence of gross blood or stool. Stool should be checked for Hemoccult positivity in the absence of gross blood. Visual inspection of the perineum may show marked skin changes or fistulas that may be associated with Crohn's disease.

Pelvic examination is similarly required in adult females. Both speculum examination and bimanual examination are required. Cultures for *Chlamydia trachomatis* and *Neisseria gonorrhoeae* should be obtained in the sexually active patient. The cervix should be checked for motion tenderness, discharge, or bleeding. The adnexae are palpated for tenderness or masses.

The male testes should be examined, looking for evidence of torsion or inflammation. Occasionally epididymitis or orchitis will present with hypogastric discomfort. A swollen testicle with a varicocele may also suggest a retroperitoneal process.

Neurologic exam should concentrate on assessing for signs of nerve root impingement. Spinal reflexes should be carefully checked as should changes in sensory or motor function.

PERITONITIS

Although the term *acute abdomen* is sometimes improperly considered synonymous with peritonitis, it is not. Peritonitis does, however, represent a concerning fraction of patients who present with acute abdominal pain. Peritonitis refers to any inflammation of the peritoneal layers. It can be localized, diffuse, sterile, or infected. The peritoneum is not a passive organ in the process. There is a peritoneal circulation as well as a capacity for clearance of contamination. An understanding of the function of the peritoneum is helpful in understanding the treatment of nonsterile peritonitis.

Infectious peritonitis is the result of contamination of the peritoneal cavity. This is considered primary if the contamination is spread via a hematogenous or lymphatic route. Secondary peritonitis is the result of direct contamination of the peritoneal cavity by an organ that is covered with peritoneum. Secondary peritonitis is considerably more common. Regardless of the method of contamination, the possible courses of disease will be the same: dissemination of the contaminant followed by either clearance and resolution or failure to clear, resulting in loculation (abscess formation) or further compromise of the host and possible death.

Primary peritonitis is rare. It results from the spread of bacteria or other microbes to the peritoneal cavity. Cirrhotics or other patients with ascites are at highest risk.[2, 3] The diagnosis requires the isolation of a single organism from the peritoneal fluid without evidence of an intraabdominal source.

Secondary peritonitis is generally the result of perforation of the gastrointestinal tract into the peritoneal cavity. The inciting events are usually inflammatory, neoplastic, traumatic, or secondary to ischemic necrosis. There are several factors that will influence the outcome of such events as described by Fry and listed in Table 1.[6]

The degree of bacterial contamination or inoculum is dependent primarily upon the site of the perforation. Gastric perforations are frequently sterile initially and result in a chemical peritonitis. Exceptions to this are patients who are achlorhydric. Bacterial concentrations increase as perforation occurs more distally in the gut. Bacterial concentration in the sigmoid colon reaches 10^{10} to 10^{11} bacteria per gram. Also, more distal perforations are associated with a higher concentration of anaerobes, particularly *Bacteroides fragilis*. Aerobes represent less than 0.1 percent of distal colonic flora. Solid debris, devitalized tissue, foreign bodies, and blood all increase the virulence of peritoneal contamination.

Peritoneal circulation helps to clear contaminants, as well as contaminates other areas of the peritoneal cavity. Since the majority of peritoneal surface is secretory, only the peritoneum adherent to the undersur-

Table 1. FACTORS INFLUENCING PERITONITIS

Factors Promoting Infection	Host Defense Factors
Bacterial inoculum	Dissemination of contaminant
Local adjuvant factors	Clearance of peritoneal fluid
Hematoma	Complement activation
Foreign body	Fibrin deposition
Devitalized tissue	Phagocytosis by macrophages and neutrophils
Systemic adjuvant factors	Loculation of bacterial collections
Hypoxemia	
Shock	
Steroids	
Malnutrition	
Comorbid medical conditions	
Peritoneal microenvironment	

face of the diaphragm is absorptive. With the forces generated by ventilatory mechanics, the fluid underlying the diaphragm is taken up via lacunae and passes directly into the lymphatics.[1,8]

Inflammation of the peritoneal cavity occurs as in other parts of the body. Macrophages located in the peritoneal cavity are activated and inflammatory mediators are released. Complement activation occurs and cytokines are released. Changes in membrane permeability and chemotactic recruitment of polymorphonuclear leukocytes ensue. These processes lead to the deposition of fibrin. This either leads to abscess formation or successful containment and clearance of the offending organism(s).

There are several host factors that are known to compromise the ability of the peritoneal cavity and the immune response to effective clear peritoneal contamination. These include the immunosuppressed host (AIDS, malnourished, burned), patients on steroids, the hypoxemic patient, shock, diabetes mellitus, and patients with protein rich ascites (carcinomatosis, cirrhosis).

LABORATORY TESTS AND RADIOGRAPHS

The purpose of laboratory tests and plain film radiographs is to confirm or exclude diagnostic possibilities that are being considered based on a proper history and physical exam. These tests should in no way replace any part of the history or physical examination. Confirmatory laboratory tests or radiographic studies are not mandatory to secure a diagnosis. They should only be ordered when they may directly influence patient care. Despite this warning, a great deal of information can still be acquired by the judicious ordering of laboratory tests.

Many institutions have policies or clinical pathways that automatically generate a series of laboratory tests to be done. Since this may be more efficient in terms of the rapid movement of a patient through an emergency room, it clearly removes the physician on the scene from the

decision making process. A further drawback of this process is that it is not uncommon for the physician (or physician extender) to see the laboratory results before he or she sees the patient. The authors doubt that this process will change in the current practice environment.

Laboratory tests may be required for two primary reasons in the patient with acute abdominal pain: to aid in the diagnosis of the patient or to assist in readying the patient for an operation. In most situations the following laboratory tests will routinely be acquired: complete blood count (CBC) and differential, liver function tests, serum electrolytes, serum creatinine and blood urea nitrogen, amylase or lipase, urinalysis, and a urine or serum β-human chorionic gonadotropin (β-hCG). The value of each test depends upon integration of these results with data already obtained from the patient.

A peripheral blood smear and CBC may reveal many things. Leukocytosis is a nonspecific marker for inflammation. The white blood cell count may be elevated, normal or even depressed in the acutely ill patient. The differential is frequently helpful. A marked elevation in the percentage of "band" form polymorphonuclear leukocytes suggests an infectious process. Leukocytosis with a normal differential is more indicative of viral processes. An elevation of atypical lymphocytes suggests possible mononucleosis (Epstein-Barr virus).

Liver function tests and pancreatic enzymes are used to further characterize possible obstructive or parenchymal liver or pancreas disorders. More important than the result of any specific liver function tests is the pattern of these results. A detailed discussion of these patterns is beyond the scope of this article. However, one can usually distinguish prehepatic, hepatocellular, or extrahepatic obstructive processes on the basis of patterns of liver function tests with little, if any, additional information. Abnormal elevations of serum pancreatic enzymes should always be considered in conjunction with the results of liver function tests. Pancreatic enzyme elevation with concomitant elevation of serum bilirubin or serum transaminases suggests obstruction of the common channel of the distal common bile duct and the pancreatic duct. Elevation of the pancreatic enzymes alone suggests either a process limited to the pancreas and its ducts or other causes of hyperamylasemia (bowel perforation or mumps).

Urinalysis can determine β-hCG. The presence of blood, crystals, leukocytes, or protein in the urine are all abnormal findings that require further investigation. The determination of pregnancy in women of child bearing age is essential. Pregnancy may represent the cause of abdominal pain, as in ectopic pregnancy, or have implications for the continued evaluation and treatment of the patient.

Plain film radiographs of the abdomen may be quite helpful in the evaluation of the patient with acute abdominal pain. A single radiographic view of the abdomen is rarely of help. The usual collection of radiographic views of the abdomen obtained includes an upright, a KUB (kidneys, ureters, bladder), and an upright chest film. This group of radiographs should be examined firstly for the patient's name and the

date of the study. After proper identification of the films, inspection should continue to search for evidence of free intraperitoneal air, air in the retroperitoneum, or air in structures that do not normally contain air (bile ducts, veins, intestinal walls, soft tissue, etc.). The pattern of gas distribution should be evaluated. The presence or absence of gas in the small bowel, colon, stomach, and rectum should be noted. In addition, the presence of air-fluid levels should be noted. The absence of gas can also be an important feature of these films. Intestines that might normally contain gas can be displaced by neoplasms or large aneurysms. The "gasless" abdomen may represent late obstruction of the bowel with complete resorption of the intraluminal air.

The outline of soft tissue structures and the solid viscera should be noted. Outlines that are normally distinct such as the psoas muscle margins or the surface of the liver may become indistinct when they are surrounded by fluid. Structures that are usually indistinct, such as parts of the serosal side bowel wall, may become very distinct if the wall is outlined on both sides by gas.

One should inspect for the presence of foreign bodies and the presence of stones (liths). Gallstones can rarely be seen on plain films. A lith in the right lower quadrant may correlate with appendicitis or ureteral lithiasis. Calcification of the vessels may suggest the presence of an aneurysm.

Numerous other imaging tests are available to the clinician including ultrasound, radionuclide imaging, computed tomography, and magnetic resonance imaging. These tests are discussed in a separate article devoted entirely to imaging. The only comment the authors would make regarding these imaging modalities is that they should be used to investigate a specific concern and not as a replacement for clinical judgment.

DIAGNOSTIC STRATEGIES

The diagnosis and treatment of the patient with an acute abdomen represents one of the greatest challenges for a surgeon. It requires a diverse array of skills. The surgeon must be more than just a skilled inquirer, examiner, or technician. He or she must also be able to see past the details of presentation as they appear on the surface. The surgeon must be able to reconstruct the facts in such a way that they reveal the subtle patterns of the myriad of processes that present with seemingly similar acute abdominal complaints.

Since caring for the patient with an acute abdomen clearly relies on judgment and experience, certain formalities of process allow for a more directed approach. It has been said that we diagnose what we look for, and we look for what we know. In order to properly evaluate patients with abdominal complaints one must be familiar with the nature of those maladies that affect the abdomen and the pattern or behavior that these processes follow. Formal discussions of each of these processes are

beyond the scope of one article, and are reviewed in other articles elsewhere in this issue. The remainder of this article will cover proposed algorithms for diagnosis of acute abdominal problems.

All patients who present with an acute abdomen must first undergo a proper history and physical examination. Patients with acutely life threatening disorders, such as a ruptured abdominal aortic aneurysm (AAA), may have to have a more cursory examination. Regardless of the nature of the patient's abdominal complaints, airway, breathing, and circulation remain of utmost priority. Figure 1 represents management of the patient who is hemodynamically unstable or has a rigid abdomen. The possibility of a ruptured AAA should be considered if the patient has a known history of an AAA, or if the symptoms of back pain, hypotension, and a pulsatile mass are present. These patients should undergo a rapid, but limited, resuscitation and be taken expeditiously to the operating room. Attempts at restoration of normal blood pressure

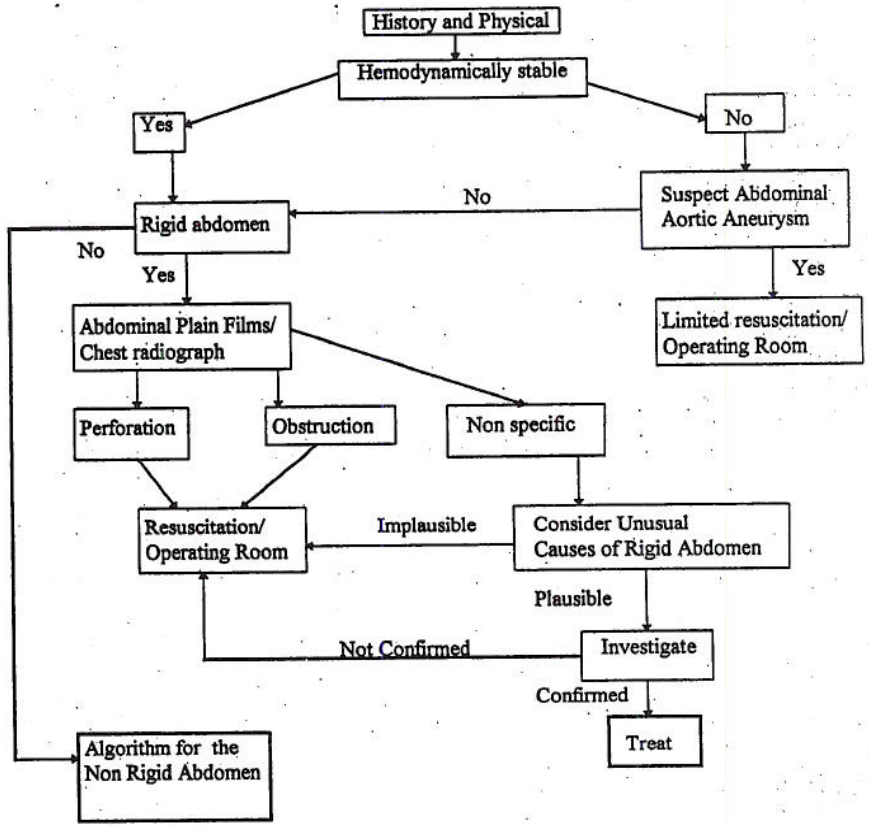

Figure 1. Acute abdominal pain.

will only delay definitive treatment and possibly worsen the degree of hemorrhage. If a leaking AAA can be satisfactorily excluded, the patient should undergo resuscitation and continued evaluation.

Most patients with a rigid abdomen will require operative management. Diffuse abdominal rigidity usually suggests perforation of a hollow viscus or infarction. Plain films of the abdomen may show evidence of free intraperitoneal air or obstruction. These patients should have a nasogastric tube placed and be brought to the operating room as soon as they are properly resuscitated. In patients with rigidity of the abdomen and normal appearing abdominal radiographs, one must consider some of the unusual causes of abdominal rigidity (acute pancreatitis, metabolic disorders, toxins, hematologic, etc.). If these are plausible and the patient is stable, they should be investigated. Otherwise the patient should be brought to the operating room for definitive evaluation and treatment.

Patients who are hemodynamically stable, and do not have diffuse abdominal rigidity, are best sorted out by the patterns of localization of signs and symptoms. Figure 2 shows the diagnosis of these patients. Signs and symptoms that are poorly localized suggest retroperitoneal or early visceral processes. Mesentric ischemia is notorious for presenting with poorly localized symptoms. Also, pain is generally out of proportion to physical findings in these patients. If AAA is suspected in the hemodynamically stable patient contrast-enhanced computed tomography should be performed. Clinical suspicion should be used to direct further evaluation of other causes that are listed in Figure 2.

The localization of abdominal signs and symptoms suggests inflammation of the parietal peritoneum and somatic sensory nerves. Pain will usually localize to the epigastrium, right upper quadrant, left upper quadrant, left lower quadrant, or right lower quadrant. These patterns are shown in Figures 2, 3, and 4. Pain in the epigastric and upper quadrants may represent the overlap of abdominal and thoracic organs. The possibilities considered in the evaluation of upper abdominal pain should include myocardial ischemia, pericarditis, esophagitis, and pleurisy. Pneumonia, pulmonary emboli, empyema, and fractured ribs can also present as upper abdominal pain. An electrocardiogram as well as plain film radiographs of the abdomen and chest should be obtained to evaluate these possibilities. Pancreatitis and penetrating duodenal ulcers classically present with epigastric pain radiating to the back. Duodenal and gastric peptic ulcers as well as biliary disorders may also initially present as epigastric pain.

Pain often localizes to one side of the patient or the other. This occurs when the somatic sensory nerves are stimulated. The fact that signs and symptoms do localize to the left or right does not signify that the process is a lateral one. Many conditions that arise in the central abdomen and peritoneal cavity may present with lateralized signs and symptoms. Some thoracic and mediastinal processes can present with left or right upper abdominal pain. Gastritis and peptic ulcer can also be variable in their side of presentation.

Disorders of the biliary tract and the liver that present acutely are

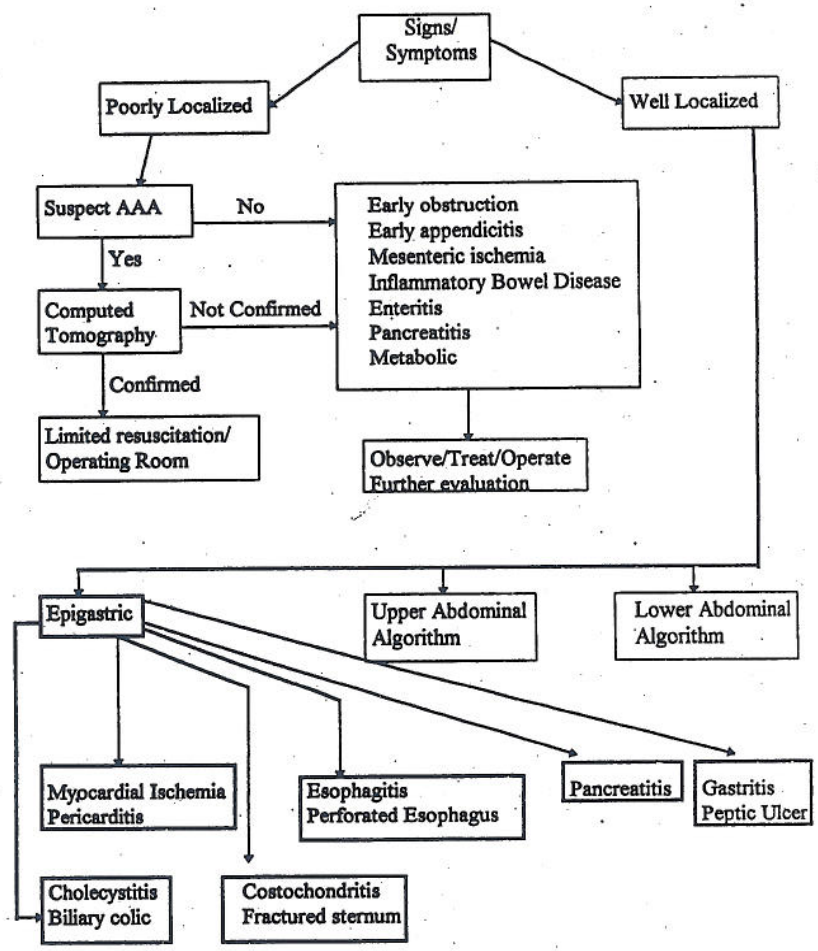

Figure 2. Nonrigid abdomen.

usually associated with right upper quadrant signs and symptoms. When jaundice is part of the clinical picture, one must examine the pattern of serum transaminases, bilirubin, and alkaline phosphatase to judge whether the process is primarily a hepatocellular defect, extrahepatic obstruction, or hemolysis. Ultrasound may be helpful in assessing the presence of gallstones and the status of the bile ducts.

Left upper quadrant pain is possibly less common as a presenting symptom in the absence of trauma than is pain elsewhere in the abdomen. The primary concerns to be addressed, when a patient presents with nontraumatic left upper quadrant pain, are vascular catastrophes such as ruptured AAA or splenic artery aneurysms, and problems related to the spleen. Computed tomographic scanning may be most helpful in this regard.

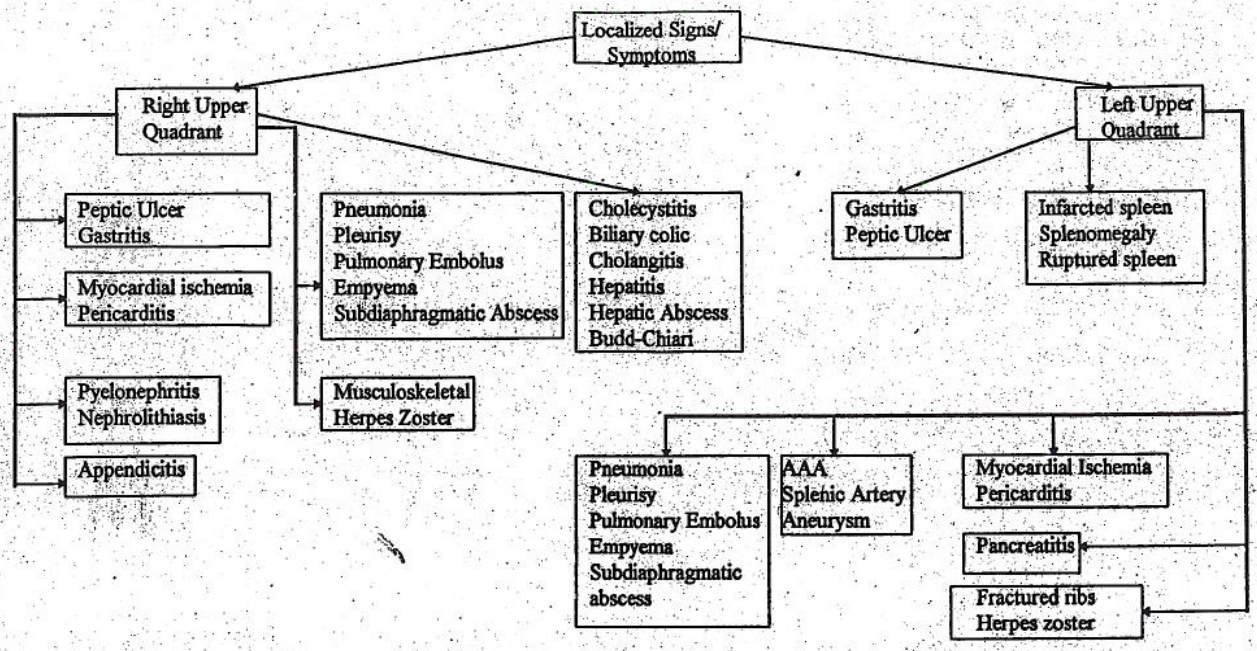

Figure 3. Upper abdomen.

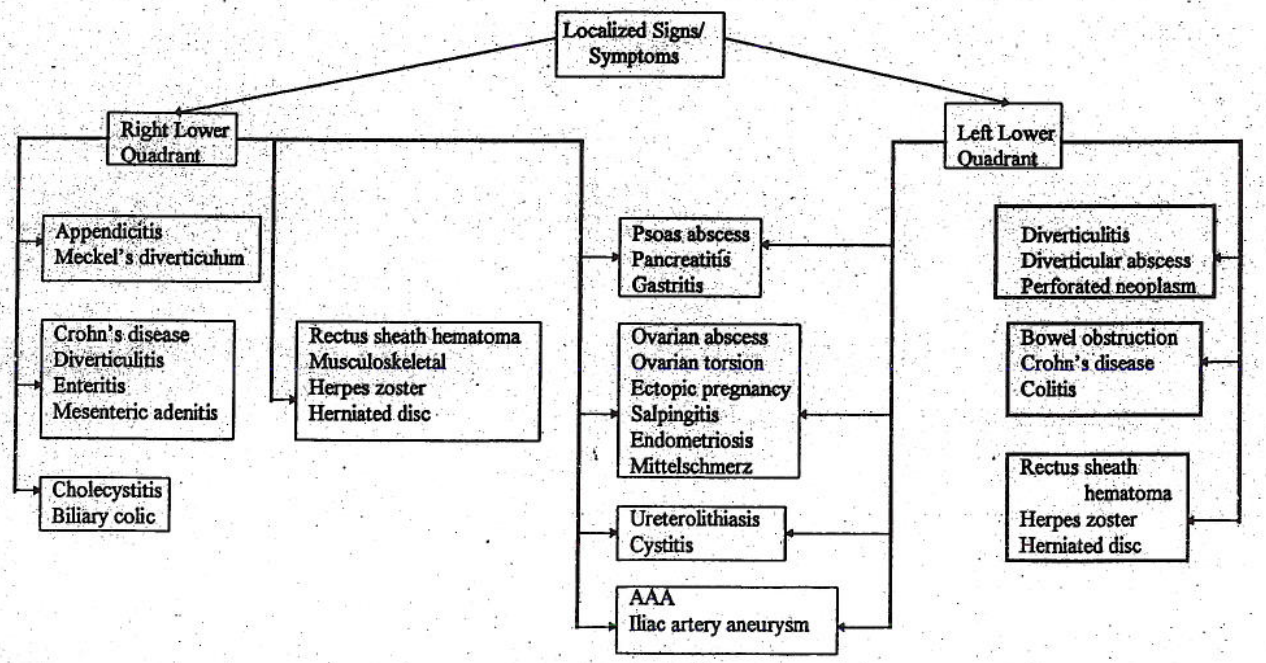

Figure 4. Lower abdomen.

Lower abdominal pain is a very common presenting symptom for the surgeon to evaluate. Clearly the gender of the patient will markedly broaden or narrow the differential diagnosis. The variability of anatomic location and mobility of the appendix, sigmoid colon, and terminal ileum provide for a wide range of presenting symptoms for a small number of disorders.

Women of child-bearing age, have a markedly increased number of possible causes of acute abdominal pain. All women who are being evaluated for abdominal pain should undergo a laboratory test for serum or urine β-hCG. Speculum and bimanual pelvic examinations are also mandatory. The examination should assess for cervical motion tenderness, and cultures should be obtained. Pelvic ultrasound is frequently helpful in the evaluation of adnexal tenderness or masses. The gynecologic cause of the acute abdomen can present with right- or left-sided symptoms, as well as midline or poorly localized symptoms. This topic is discussed in much greater depth in an article elsewhere in this issue.

Vascular problems, such as AAA or iliac artery aneurysms, may also present as lower abdominal pain that is localized or not. Gastritis and pancreatitis rarely present as lower abdominal pain. Cystitis and ureterolithiasis sometimes present as excruciating lower abdominal pain.

Appendicitis classically presents with right lower quadrant pain, but has such a myriad of presentations that it should be considered in any patient with abdominal pain. Terminal ileal processes, such as Crohn's disease and intussusception, may present with right lower quadrant pain and may mimic appendicitis. An inflamed Meckel's diverticulum may also present as appendicitis would. Biliary tract problems occasionally present as right lower quadrant pain.

Sigmoid diverticulosis is extremely common in the United States population. Diverticulitis classically presents with left lower quadrant pain and fever. This may be accompanied by obstruction, contained paracolic abscess, or free intraperitoneal rupture. Owing to the variability of location of the sigmoid colon, presenting symptoms may be located elsewhere in the abdomen. Occasionally diverticulitis will present as a small bowel obstruction, when a loop of small intestine is adherent to the inflamed diverticulum. Computed tomographic scanning may be helpful in assessing the patient with presumed diverticulitis who has a mass on examination or who fails to respond to intravenous antibiotics. Colitis and enteritis may present in any number of ways. A history of diarrhea or associated viral symptoms may be helpful in making the diagnosis. Ulcerative colitis and Crohn's colitis are usually associated with Hemoccult-positive stools.

Abdominal wall pathology can also mimic an intra-abdominal process. Rectus sheath hematomas, musculoskeletal injuries, herpes zoster, and spinal nerve impingement are also well known causes of abdominal pain. Psoas muscle abscess and hematomas can present as right- or left-sided abdominal pain. Patients who are receiving anticoagulants should be strongly considered for these possibilities.

When considering the use of imaging, the presence of localized symptoms can be useful in directing the choice of study. Symptoms that suggest retroperitoneal processes are best evaluated by computed tomographic scanning. Right upper quadrant and epigastric symptoms are frequently most effectively evaluated by ultrasonography. Left upper quadrant symptoms and left lower quadrant symptoms suggestive of diverticulitis are also best imaged with computed tomography. Right lower quadrant symptoms and symptoms that are suggestive of gynecologic processes are best evaluated with ultrasonography or laparoscopy. The choice of imaging technology must take into account the cost, the likelihood that clinical benefit will be gained, the possibility of therapeutic gain, and the institutional expertise with the chosen technology.

CONCLUSION

The ability to completely discuss the topic of the patient with an acute abdomen far exceeds the limits of one article or even a collection of articles. This discussion is intended to cover the basics: the taking of a proper history, the performance of a complete physical examination, understanding the fundamental anatomy and physiology of the abdomen, and integration of these concepts into algorithms that allow us to determine the cause of a patient's suffering. The remaining articles in this issue of the *Surgical Clinics of North America* have been written with the intent of exploring the state of the art in many subsets of these patients and to evaluate how technologic advances in the past decade or so have changed our approach to these challenging patients.

References

1. Allen L, Weatherford T: Role of fenestrated basement membrane in lymphatic absorption from the peritoneal cavity. Am J Physiol 197:551–554, 1956
2. Conn HO, Fessel JM: Spontaneous bacterial peritonitis in cirrhosis: Variations on a theme. Medicine 50:161–197, 1971
3. Conn HO: Spontaneous bacterial peritonitis, multiple revisitations. Gastroenterology 70:455–457, 1976
4. Klein KB, Mellinkoff SM: Approach to the Patient with Abdominal Pain. Philadelphia, JB Lippincott, 1991, p ???
5. Koch MO, McDougal WS: Urologic cause of the acute abdomen. Surg Clin North Am 68:399–413, 1988
6. Fry DE: Surgical Infection. *In* O'Leary JP (ed): The Physiologic Basis of Surgery. 2nd ed. Baltimore, Williams and Wilkins, 1996, pp 184–227
7. McFadden DW, Zinner MJ: Approach to the Patient with the Acute Abdomen and Fever of Abdominal Origin. Philadelphia, JB Lippincott, 1991
8. Tsilibary EC, Wissig SL: Absorption from the peritoneal cavity: SEM study of the mesothelium covering the peritoneal surface of the muscular portion of the diaphragm. American Journal of Anatomy 149:127–132, 1977

Address reprint requests to
Ronald F Martin, MD
72 West Street
Portland, Maine, 04102